Orchard PATHOLOGY

PATHOLOGY REPORTS

Orchard Pathology Sample Patient Reports

Highly Configurable & Flexible Software

With more than 25 years of LIS experience, the scalability and flexibility of Orchard's laboratory information systems facilitates an advanced level of configurability that enables Orchard to support a diverse client base. More than 1,500 laboratories across the country have turned to Orchard Software—including all types and sizes of multi-site and multi-specialty clinics and physician office laboratories, hospitals, regional reference labs, fertility clinics, veterinary labs, university student health services, research laboratories, toxicology and pain management clinics, and public health organizations.

Decorated Product Suite Empowers Laboratories

Our award-winning laboratory information systems utilize process automation, robust interface and integration tools, and rules-based technology to simplify laboratory workflow and expertly address regulatory and integration issues.

Orchard® TRELLIS™

Integrates POCT results into your EHR

Eases POCT oversight for POC coordinators

Information dashboard keeps you informed of POCT status

Tracks training and certification dates for all testing personnel

Orchard® HARVEST™

Seamless integration for instrument, EHR/HIS, billing, and reference laboratory interfaces

Rules-based decision support and error-proofing technology

User-configurable patient report formats

Tools for data mining and business analytics

Orchard® PATHOLOGY™

An all-inclusive CP/AP information system

Consolidated results on a single patient report

Structured data for synoptic reporting

Orchard® Web AP for remote user access

Orchard® SEQUOIA™

Enterprise-class LIS utilizing Microsoft® SQL® Server architecture

Single application with a segmental design

Tested and proven Interface Engine provides seamless interoperability

Analytics to support business intelligence and population health management

Orchard® COPIA®

A lab system integration hub bringing locations and diagnostic data together

Electronic integration to your clients' EHRs

Web-based access for clients without an EHR

Training and tools to implement your own EHR interfaces

ORCHARD PATHOLOGY LABORATORIES

Robert Bush, MD
Laboratory Director

701 Congressional Blvd.
Carmel, Indiana 46032

Phone: (800) 555-1234
Fax: (317) 573-2528

Prostate Biopsy Pathology Report

Final

PATIENT INFORMATION

Patient Name: **Patient, John**

M, Age 34 | DOB: 4/12/1979

Phone: (123) 555-1234

EMR: (123) 555-1234

CLINICAL INFORMATION:
8.6; Oct. 2012 / Elevated PSA

PHYSICIAN INFORMATION

James Provider, MD

ABC Medical

400 Royal Drive

Anytown USA, 12345

Phone: (123) 555-4321

Fax: (999) 555-4322

ACCESSION NUMBER

12XX0002

COLLECTION DATE: 2/15/2013

RECEIVED DATE: 2/15/2013

REPORT DATE: 2/17/2013

TAT: [26 hours]

PROSTATE BIOPSY DIAGRAM AND MICROSCOPIC IMAGES

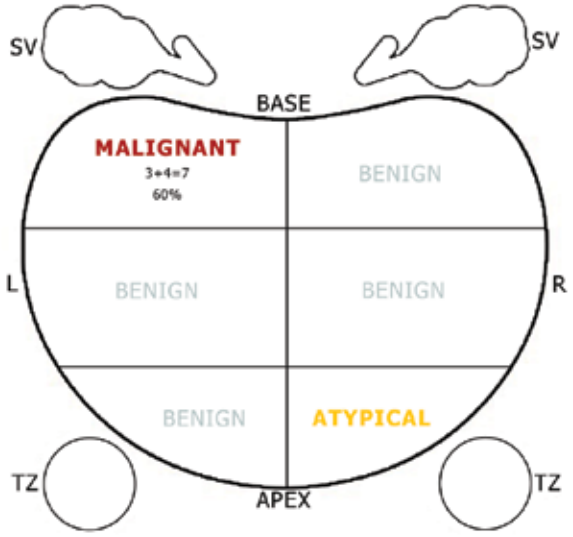

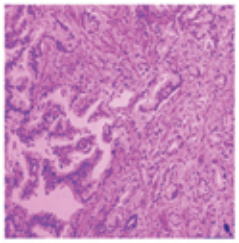

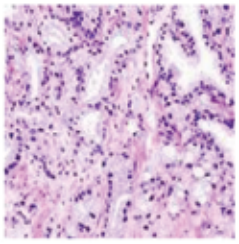

FINAL DIAGNOSIS

Site	Gleason Score	Diagnosis	Tumor %	Tumor Length (mm)	Core Length (mm)	# Cores
1 Left Base	3+4=7	**ADENOCARCINOMA**	60	6	10	1
2 Left Mid		Benign		0	10	1
3 Left Apex		Benign		0	10	1
4 Right Base		Benign		0	10	1
5 Right Mid		Benign		0	10	1
6 Right Apex		**HGPIN**		0	10	1

John Pathologist

Electronically Signed on 2/17/2013 at 11:42 am

Orchard Pathology Laboratories, Inc.
Robert Bush, MD, Laboratory Director
CLIA ID#: 01D000XXX000
CAP #: 123456

701 Congressional Blvd.
Carmel, Indiana 46032
Phone: (800) 555-1234
Fax: (317) 573-2528

Patient Name:	Patient, Jane A.	**Provider:**	James Provider, MD
Sex:	F	**Account Number:**	
DOB:	06/22/1955	**Client:**	ABC Medical
Patient ID:	12345-6	**Client Address:**	1234 Anystreet Anytown, USA 12345
Collection Date:	10/02/2013 08:57		
Received Date:	10/02/2013 08:57	**Telephone:**	(123) 555-1234
Reported:	10/03/2013 10:02	**Accession #:**	S-01-012345-6

Surgical Pathology Report

FINAL DIAGNOSIS

A. Soft Tissue, Left Supraclavicular, Core Needle Biopsy:
MALIGNANT LYMPHOMA, LARGE CELL ANAPLASTIC TYPE, ALK-1 NEGATIVE

B. Skin, Upper Back, Incisional Biopsy:
MALIGNANT LYMPHOMA, LARGE CELL ANAPLASTIC TYPE, ALK-1 NEGATIVE

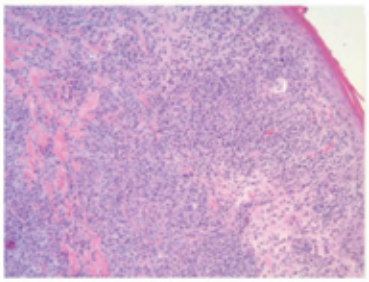
S-01-012345-6

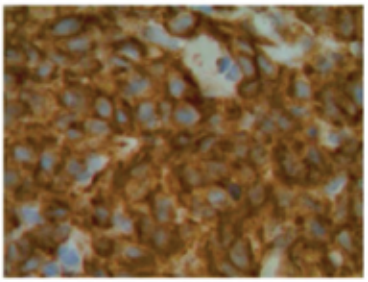
S-01-012345-6

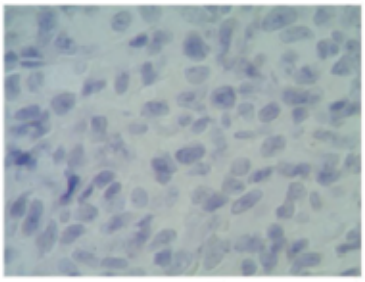
S-01-012345-6

Specimen: Left Supraclavicular Skin, Upper Back

Preoperative Diagnosis Probable malignancy. History of recent left supraclavicular mass of rapid onset with an upper back skin nodule. CT scan shows mediastinal adenopathy without other organ masses.

Gross Examination
Received are two formalin filled containers labeled "Jane Patient"

A. Container A is labeled "Needle biopsy left supraclavicular area" and holds 2 cylindrical shaped fragments measuring 2 mm in diameter and 10 and 13 mm in length. The specimen is poured into a filter bag and entirely submitted in cassette A.

B. Container B is labeled "Skin Upper Back" and holds a wedge-shaped fragment of skin measuring 8.0 x 10.0 x 6.0 cm. The specimen is dissected and entirely submitted in cassette B.

Performed by: A. Tech

Microscopic Examination
The Final Diagnosis for each specimen is based on a microscopic examination of the tissues or preparation from these tissues.

Orchard Pathology Laboratories, Inc.
Robert Bush, MD, Laboratory Director
CLIA ID#: 01D000XXX000
CAP #: 123456

701 Congressional Blvd.
Carmel, Indiana 46032
Phone: (800) 555-1234
Fax: (317) 573-2528

Patient Name:	Patient, Jane A.	**Provider:**	James Provider, M.D.
Sex:	F	**Account Number:**	
DOB:	06/22/1955	**Client:**	ABC Medical
Patient ID:	12345-6	**Client Address:**	1234 Anystreet Anytown, USA 12345
Collection Date:	10/02/2013 08:57		
Received Date:	10/02/2013 08:57	**Telephone:**	(888) 876-5432
Reported:	10/03/2013 10:02	**Accession #:**	S-01-012345-6

Comment:

Both of these biopsies show similar neoplastic cell infiltrates that have the characteristic isolated large poorly differentiated (anaplastic) cells with oval to reniform nuclei with large single nucleoli and a flocculent eosinophilic cytoplasm. In the supraclavicular space there is necrosis and inflammation with the neoplastic cells oriented around vessels. The skin lesion is earlier involvement with infiltrates in the deep and superficial dermis. A panel of immunohistochemical stains was done that show a pattern consistent with this type of lymphoma (see below), which includes a strong CD 30 positive pattern.

Special Stains Performed	
CD30	Positive
CD45	Weakly Positive
CD3	Negative
CD4	Positive
CD20	Negative
ALK-1	Negative

John Pathologist

John Pathologist, MD
Electronically signed: 10/03/2013 09:13

CPT Codes: 88305(x2), 88342(x14)

ICD9 Codes: 202.88

Orchard Pathology Laboratories, Inc.
Robert Bush, MD, Laboratory Director
CLIA ID#: 01D000XXX000
CAP #: 123456

701 Congressional Blvd.
Carmel, Indiana 46032
Phone: (800) 555-1234
Fax: (317) 573-2528

Patient Name:	Patient, John C.	**Provider:**	James Provider, MD
Sex:	M	**Account Number:**	
DOB:	04/12/1979	**Client:**	ABC Medical
Patient ID:	54321-6	**Client Address:**	1234 Anystreet Anytown, USA 12345
Collection Date:	10/15/2013 17:45		
Received Date:	10/15/2013 18:52	**Telephone:**	(123) 555-1234
Reported:	10/16/2013 10:44	**Accession #:**	S-01-543210-6

Surgical Pathology Report

FINAL DIAGNOSIS

A. Ascending Colon
SESSILE SERRATED ADENOMA (POLYP) WITH LOW-GRADE ADENOMATOUS DYSPLASIA.

B. Sigmoid Colon
TUBULAR ADENOMA

COMMENT:
Patients with sessile serrated adenomas, especially with cytologic dysplasia, are at increased risk for the development of adenocarcinoma showing microsatellite instability. This progression may occur at a more rapid rate than with traditional adenomas. Complete endoscopic excision is recommended if clinically appropriate. If unresectable, repeat colonoscopy at a shortened interval (1 year), with sampling of suspicious areas or surgical resection possibly warranted.

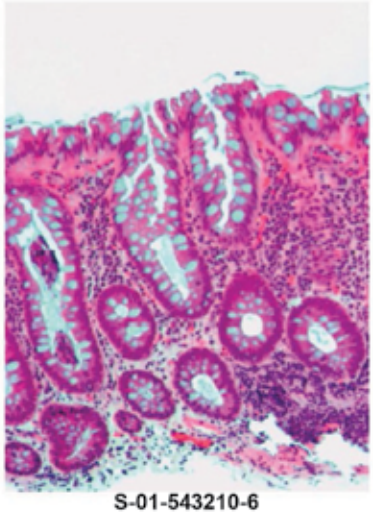

S-01-543210-6

Specimen: 2 cm polyp ascending colon 2 mm polyp in sigmoid colon

Clinical History: Screening colonoscopy. Maternal hx of adenocarcinoma of colon age 57

Gross Examination

A. The first container is labeled "ascending colon." It contains a polypoid piece of tan mucosal tissue measuring 2.0 cm in greatest dimension. The polyp margin is inked, sectioned, and submitted in cassettes Al and A2.

B. The second container is labeled "sigmoid colon." It contains one piece of light tan mucosal tissue 0.2 cm in greatest dimension. Entirely submitted in cassette B.

Microscopic Examination

Microscopic Examination performed supportive of the Final Diagnosis above.

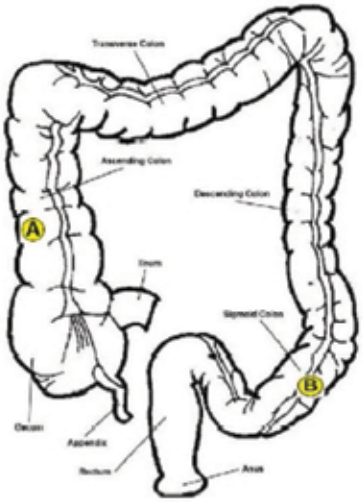

S-01-543210-6

John Pathologist

John Pathologist, MD
Electronically signed: 10/16/2013 10:44

Case number: S-01-543210-6
END OF REPORT

Reviewed by: _____

Orchard Pathology Laboratories, Inc.
700 Congressional Blvd.
Carmel, Indiana 46032
Phone: (800) 555-1234
Fax: (317) 573-2528

Robert Bush, MD, Laboratory Director
CLIA ID#: 01D000XXX000

Patient Name:	**Patient, Jane A.**			**Case number:**	B08-0006
Patient ID:	12345-6			**Collection Date:**	08/12/2013 08:40
Date of Birth:	06/22/1955	**Age:** 58	**Sex:** F	**Received Date:**	08/12/2013 08:40
				Reported:	08/16/2013 10:02
Provider:	James Provider, MD				

Bone Marrow Pathology Report

FINAL DIAGNOSIS

WHO Acute Myeloid Leukemia Not Otherwise Specified: FAB Acute Myelomoncytic Leukemia (M4)

Bone Marrow Biopsy, Aspirate and Particle Preparation:
1. Acute Myeloid Leukemia with marked hypercellularity, numerous blasts (67%), and eosinophilia (21 %).
2. Reduced Trilineage Hematopoesis.

Peripheral Blood:
1. Acute Myeloid Leukemia with leukocytosis including numerous blasts (40%), monocytosis (25%), and eosinophilia (16%).
2. Anemia and thrombocytopenia.

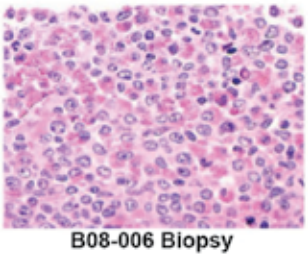
B08-006 Biopsy

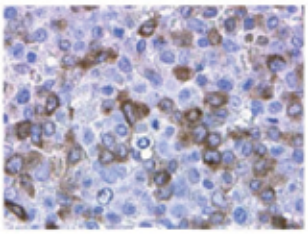
B08-006 IHC

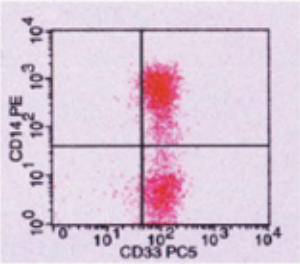

B08-006


B08-006

Flow Cytometry Interpretation

Flow cytometric immunophenotyping studies performed on bone marrow demonstrated numerous CD34 positive/CD117 positive myeloid blasts (14/22% positive); these cells coexpressed the myeloid markers CD13/33. Many expressed HLA-DR and TdT, also markers of myeloid immaturity. Also, there was a distinct population of cells that expressed the monocytoid marker, CD14.

Clinical History: A 58-year-old female without any significant past medical history, developed symptoms of sinus pressure and headache for approximately three weeks. These were thought to be sinusitis and treated with oral antibiotics (Bactrim) and antihistamines. Subsequently she developed gingival hyperplasia and was found to have a white blood cell count of over 70xl0^9/L.

Microscopic Examination
Bone Marrow biopsy and aspirate were performed with the following remarkable and abnormal differential counts:

Blasts:	67.0%	(normal 0.0-2.0)
Eos Myelo/Meta:	15.0%	(normal 1.0-4.0)
Eos Band:	3.7%	(normal 1.0-2.0)
Eos Seg:	2.3%	(normal 1.0-2.0)

The marrow was markedly hypercellular (approximately 100%). The predominant cells were blasts but eosinophils also appeared markedly increased. The blasts in the marrow were generally large with many having a moderate amount of

Orchard Pathology Laboratories, Inc.
700 Congressional Blvd.
Carmel, Indiana 46032
Phone: (800) 555-1234
Fax: (317) 573-2528

Robert Bush, MD, Laboratory Director
CLIA ID#: 01D000XXX000

Patient Name:	**Patient, Jane A.**			**Case number:**	B08-0006
Patient ID:	12345-6			**Collection Date:**	08/12/2013 08:40
Date of Birth:	06/22/1955	**Age:** 58	**Sex:** F	**Received Date:**	08/12/2013 08:40
				Reported:	08/16/2013 10:02
Provider:	James Provider, MD				

Bone Marrow Pathology Report

FINAL DIAGNOSIS

WHO Acute Myeloid Leukemia Not Otherwise Specified: FAB Acute Myelomoncytic Leukemia (M4)

Bone Marrow Biopsy, Aspirate and Particle Preparation:
1. Acute Myeloid Leukemia with marked hypercellularity, numerous blasts (67%), and eosinophilia (21 %).
2. Reduced Trilineage Hematopoesis.

Peripheral Blood:
1. Acute Myeloid Leukemia with leukocytosis including numerous blasts (40%), monocytosis (25%), and eosinophilia (16%).
2. Anemia and thrombocytopenia.

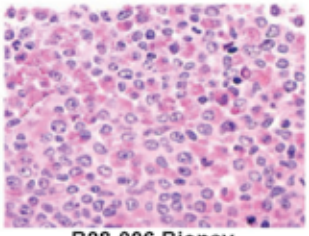
B08-006 Biopsy

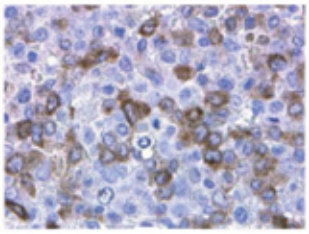
B08-006 IHC

Flow Cytometry Interpretation

Flow cytometric immunophenotyping studies performed on bone marrow demonstrated numerous CD34 positive/CD117 positive myeloid blasts (14/22% positive); these cells coexpressed the myeloid markers CD13/33. Many expressed HLA-DR and TdT, also markers of myeloid immaturity. Also, there was a distinct population of cells that expressed the monocytoid marker, CD14.

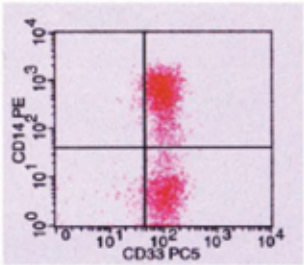

B08-006

Clinical History: A 58-year-old female without any significant past medical history, developed symptoms of sinus pressure and headache for approximately three weeks. These were thought to be sinusitis and treated with oral antibiotics (Bactrim) and antihistamines. Subsequently she developed gingival hyperplasia and was found to have a white blood cell count of over 70xl0^9/L.


B08-006

Microscopic Examination
Bone Marrow biopsy and aspirate were performed with the following remarkable and abnormal differential counts:

Blasts:	67.0%	(normal 0.0-2.0)
Eos Myelo/Meta:	15.0%	(normal 1.0-4.0)
Eos Band:	3.7%	(normal 1.0-2.0)
Eos Seg:	2.3%	(normal 1.0-2.0)

The marrow was markedly hypercellular (approximately 100%). The predominant cells were blasts but eosinophils also appeared markedly increased. The blasts in the marrow were generally large with many having a moderate amount of

Orchard Pathology Laboratories, Inc.
700 Congressional Blvd.
Carmel, Indiana 46032
Phone: (800) 555-1234
Fax: (317) 573-2528

Robert Bush, MD, Laboratory Director
CLIA ID#: 01D000XXX000

Patient Name:	**Patient, Jane A.**			**Case number:**	B08-0006
Patient ID:	12345-6			**Collection Date:**	08/12/2013 08:40
Date of Birth:	06/22/1955	**Age:** 58	**Sex:** F	**Received Date:**	08/12/2013 08:40
				Reported:	08/16/2013 10:02
Provider:	James Provider, MD				

medium-to-light blue cytoplasm. The nuclear chromatin was dispersed, or partially dispersed, but usually without a nucleolus. Immunohistochemistry was performed and findings were as follows: Approximately 10% of the young cells appeared to be reactive for peroxidase, a histochemical marker for myeloid differentiation. Approximately 10% of the blasts were weakly positive for nonspecific esterase (NSE), a histochemical marker for monocytoid differentiation. Greater than 50% of cells were positive for CD68, an immunohistochemical marker for myeloid cells and especially macrophages. Approximately 30% of cells were positive for lysozyme, another immunohistochemical marker for myeloid and particularly monocytoid lineage cells.

Cytogenetics/FISH:
Conventional karyotypic analysis suggested initially that one cell line represented by most of the examined cells showed a translocation between the long arms of chromosomes 5 and 22. Specifically 46XX t(5 ;22)(q31 ;q 11.2). However, FISH studies performed subsequently suggested a more complex three-way translocation involving chromosomes 12, 5, and 22: [t(5;12,22)(q33;p13;q13)]. FISH studies utilized the ERG1(5q31), the telomeric DNA probes for 5q and 22q, and the TEL DNA (12p13) probes to further elucidate the breakpoints. These studies showed that one 5qtel signal was translocated from the der(5) to the der(22) (Seimon5q.tif) and one 22qtel signal was translocated form the der(22) to the short arm of chromosome 12 (Seimon22q.tif), and one TEL signal was translocated from the short arm of der(l2) to the long arm of der(5). The FISH findings confirmed a complex three-way translocation involving the short arm of chromosome 12 in addition to the long arms of chromosomes 5 and 22 as was detected by classical cytogenetics. The EGR1(5q31) probe showed that the EGRl gene locus was preserved on the der(5) suggesting that the breakpoint was distal to the ERGl locus therefore modifying the karyotype to be 46,XX,t(5;12;22)(q33;pl3;q13)

Laboratory Findings

WBC	78 x 10A9/L	(normal 3.8 -10.6 x101'9/L)
RBC	2.69 x1 01\ 12/L	(normal 3. 7 3 - 4. 89 x1 01\ 12/L)
Hemoglobin	9.0 g/dl	(normal 11.6 - 14.6 gldl)
Hematocrit	25.6 %	(normal 34.1 - 43.3 %)
MCV	95.4 fl	(normal 82.6 - 97.4 jl)
MCH	33.5 pg	(normal 27.8 - 33.4 pg)
MCHC	35.1 g/dl	(normal 32.7 - 35.5 gldl)
RDW	14.6%	(normal 11.8 - 15.2%)
PLT	43 x101.9/L	(normal 156 - 369 x10A9/L)
POLYS	1 %; ABS 0.8	(normal 2.24 - 7.68)
LYMPHS	13%; ABS 10.0	(normal 0.80 - 3.65)
MONOS	25%; ABS 23.3	(normal 0.30 - 0.90)
EOS	16%; ABS 10.6	(normal 0.00 - 0.40)
BLASTS	40%; ABS 29.2	
PRO	1%; ABS 0.8	
MYELO	2%; ABS 1.60	
META	2%; ABS 1.60	

John Pathologist

John Pathologist, MD
Electronically signed: 08/16/2013 09:44

ORCHARD PATHOLOGY LABORATORIES

Robert Bush, MD
Laboratory Director

701 Congressional Blvd.
Carmel, Indiana 46032

Phone: (800) 555-1234
Fax: (317) 573-2528

Molecular Pathology Report

Final

PATIENT INFORMATION

Patient Name: **Patient, Josie**
F, Age 62 | DOB: 8/9/1951
Phone: (123) 123-1234
EMR: (123) 123-1234

PHYSICIAN INFORMATION

James Provider, MD
ABC Medical
400 Royal Drive
Anytown USA, 12345
Phone: (888) 876-5432
Fax: (999) 876-5432

ACCESSION NUMBER

M07-0134

COLLECTION DATE:	2/20/2013
RECEIVED DATE:	2/20/2013
REPORT DATE:	2/21/2013

Molecular Pathology Report

Specimen Type: Voided Urine
Indication for Study: Bladder Cancer
FISH Probes: Centromeres of 3, 7 and 17. Locus p16 at 9p21
Interphase Nuclei Scored: 200

Results: POSITIVE for the 3, 7, and 17 centromeres. Normal for the 9p21 probe.

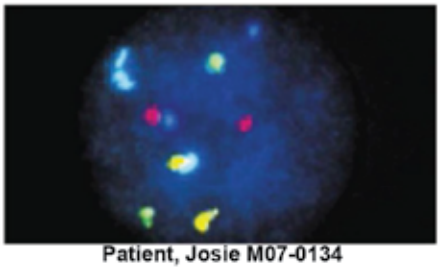

Patient, Josie M07-0134

FISH Interpretation

Molecular detection of aneuploidy for chromosomes 3, 7, 17, and the loss of locus 9p21 is performed by fluorescence in situ hybridization (FISH) using the Vysis UroVysion bladder cancer recurrence commercial assay. This assay is performed according to modification of the FDA approved method, which has been validated by Orchard Pathology Laboratories.

Support for the interpretation of this case may have included the use of immunohistochemistry, and/or in situ hybridization tests that were performed by Orchard Pathology Laboratories. These tests have not been cleared or approved by the U.S. Food and Drug Administration. The FDA has determined that such clearance or approval is not necessary. These tests are used for clinical purposes and should not be regarded as investigational or for research. This laboratory is certified under the Clinical Laboratory Improvement Amendments of 1988 (CLIA) as qualified to perform high complexity clinical laboratory testing.

Patient Result: FISH POSITIVE (POLYSOMY)

(A positive result indicates a gain of more than one chromosome in 4 or more cells, or the homozygous loss of locus 9p21 in 12 or more cells.)

*Comment: *The Vysis UroVysion FISH kit for the diagnosis and monitoring of bladder cancer has been approved by the FDA. This kit is designed to detect aneuploidy for chromosomes 3, 7, and 17 and the loss (deletion) of the 9p21 locus via FISH in urine specimens. The performance of the probes in this kit has been determined by Premier Laboratories and this test is utilized for clinical purposes.*

John Pathologist

John Pathologist, MD
Electronically signed: 2/21/2013 09:44

Case number: M07-0134
END OF REPORT (Final)

Reviewed by: _____

Orchard Pathology Laboratories, Inc.

700 Congressional Blvd.
Carmel, Indiana 46032
Phone: (800) 555-1234
Fax: (317) 573-2528

Robert Bush, MD, Laboratory Director
CLIA ID#: 01D000XXX000

Patient Name:	**Patient, Michael E.**	**Case number:**	S07-0110
Patient ID:	555333	**Collection Date:**	03/29/2013 09:42
Date of Birth:	12/14/1957 **Age:** 56 **Sex:** M	**Received Date:**	03/29/2013 09:42
		Reported:	03/30/2013 11:26
Provider:	James Provider, MD		

Surgical Pathology Report

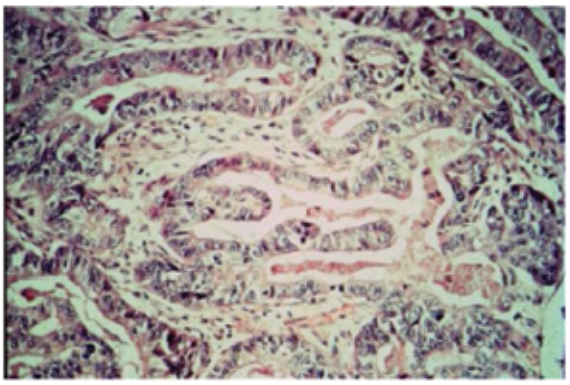

Patient, Michael E. S07-0110

FINAL DIAGNOSIS

A. GE Junction: ADENOCARCINOMA of the esophagus.

B. Antrum: Non-neoplastic gastric antral mucosa, negative for inflammation. Stain for Helicobacter pylori microorganisms is negative.

Gross Examination

A. Received in formalin and labeled "Patient, Michael E." and "EG Junction" are multiple fragments of tan tissue measuring 0.7 x 0.4 x 0.2 cm in aggregate. The specimen is entirely submitted in one cassette labeled "A."

B. Received in formalin and labeled, "Patient, Michael E." and "Antrum" are two fragments of pink-tan tissue measuring 0.2 x 0.2 x 0.2 cm. The specimen is entirely submitted in one cassette labeled "B."

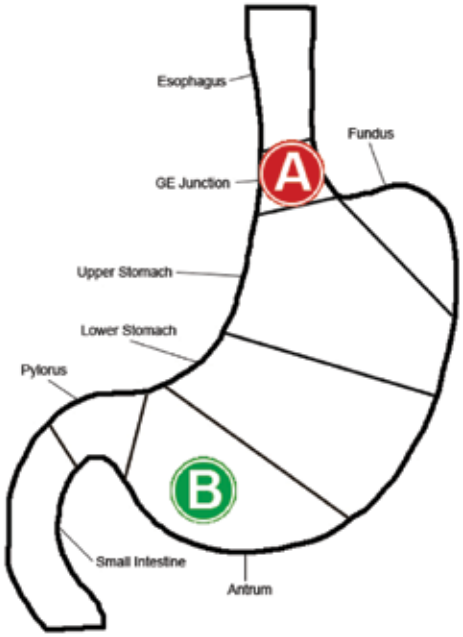

John Pathologist

John Pathologist, MD
Electronically signed: 03/30/2013 09:44

Orchard Pathology Laboratories, Inc.
700 Congressional Blvd.
Carmel, Indiana 46032
Phone: (800) 555-1234
Fax: (317) 573-2528

Robert Bush, MD, Laboratory Director
CLIA ID#: 01D000XXX000

Patient Name:	**Patient, Julie B.**			**Case number:**	G07-0062
Patient ID:	444222			**Collection Date:**	06/13/2013 21:14
Date of Birth:	09/05/1968	**Age:** 45	**Sex:** F	**Received Date:**	06/13/2013 21:14
				Reported:	06/14/2013 02:43
Provider:	James Provider, MD				

Final Cytology GYN Report

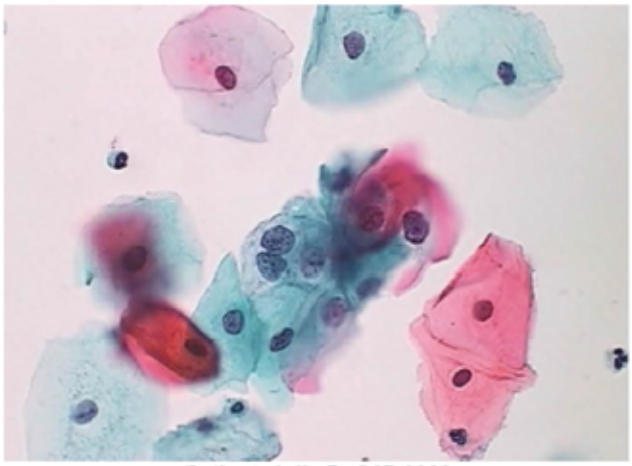
Patient, Julie B. G07-0062

Interpretation/Result: Epithelial Cell Abnormalities: ASCH - Atypical squamous cells cannot exclude HSIL

Organisms: Normal Findings

Specimen Adequacy: Satisfactory for Evaluation - Presence of Endocervicali Transformation Zone Component

CLINICAL INFORMATION

Date Last Pap Feb 2012
GYN Source: Cervical/endocervical
Date LMP/Menopause: 05/22/2013
Clinical Impressions: Oral contraceptives
Previous Treatment: None
Previous PAP: Atypical; ASCUS

**The Pap smear is a screening test, not a diagnostic procedure and should not be used as the sole means of detecting cervical cancer. Both false-positive and false-negative reports do occur.*

Human Papilloma Virus HPV Assay by in-situ hybridization
16, 18, 31, 33, 35, 39, 45, 51, 52, 56, 58, 66 ..... NOT DETECTED

Laboratory Findings

Historical Diagnosis:
Thin Prep PAP Test Case Number: G06-42-01 Issued: 06/12/07
INTERPRETATION/RESULT: Epithelial Cell Abnormalities: ASCUS-Atypical squamous cells of undetermined significance

Screened by: M Jones, CT

John Doctor

John Doctor, MD
Electronically signed: 06/14/2013 02:31

Orchard Pathology Laboratories, Inc.
Robert Bush, MD, Laboratory Director
CLIA ID#: 01D000XXX000
CAP #: 123456

701 Congressional Blvd.
Carmel, Indiana 46032
Phone: (800) 555-1234
Fax: (317) 573-2528

Patient Name:	Patient, Julie B.	**Provider:**	James Provider, MD
Sex:	F	**Account Number:**	
DOB:	09/05/1968	**Client:**	ABC Medical
Patient ID:	444222	**Client Address:**	1234 Anystreet Anytown, USA 12345
Collection Date:	09/15/2013 17:45		
Received Date:	09/15/2013 18:52	**Telephone:**	(123) 555-1234
Reported:	09/16/2013 10:44	**Accession #:**	P07-6824

Cytology GYN Report

General Categorization:
Epithelial cell abnormality (See Interpretation)

Interpretation:
Atypical squamous cells of undetermined significance (ASCUS)
Atypical koilocytosis, cytoplasmic and nuclear change consistent with HPV effect
HPV, High Risk - Positive; HPV, Type 16 - Positive; HPV, Type 18 - Negative
Chlamydia (CT) - Positive; Gonorrhoeae (GC) - Negative

The Pap smear is a cancer screening test that has an overall1 5-25% false negative rate. For this reason, an annual Pap smear is recommended. Please discuss this with your patients.

CLINICAL INFORMATION
Type of test: High Risk Screening
Date LMP: 5/5/10
Clinical diagnosis: None given
Clinical history: None given
Previous Smears: Unknown

Specimen type: Liquid based
Specimen source: Cervical, Endocervical
Specimen Adequacy: Smear is satisfactory for evaluation

Comment: The Thin Prep Imaging System from Hologic, Inc. was used to pre-screen this Pap smear.
Primary screening reported Pap abnormalities. Pathologist review was required to interpret the primary screener review.

Pap screening performed by: Breakthrough Cytology Services, 527 Joanne Lane, Dekalb, IL 60115.
Interpretation required by undersigned pathologist at Orchard Pathology Laboratories, 701 Congressional Blvd, Carmel, IN 46032.

09/16/2013
Cy Totech, CT, ASCP

09/16/2013 Authenticated by:

John Doctor

John Doctor, MD
Electronically signed: 06/14/2013 02:31

Orchard Pathology Laboratories, Inc.
Robert Bush, MD, Laboratory Director
CLIA ID#: 01D000XXX000
CAP #: 123456

701 Congressional Blvd.
Carmel, Indiana 46032
Phone: (800) 555-1234
Fax: (317) 573-2528

Patient Name:	Patient, Julie B.	**Provider:**	James Provider, MD
Sex:	F	**Account Number:**	
DOB:	09/05/1968	**Client:**	ABC Medical
Patient ID:	444222	**Client Address:**	1234 Anystreet Anytown, USA 12345
Collection Date:	09/15/2013 17:45		
Received Date:	09/15/2013 18:52	**Telephone:**	(123) 555-1234
Reported:	09/16/2013 10:44	**Accession #:**	S07-6825

DERMATOPATHOLOGY REPORT

FINAL DIAGNOSIS

1) SKIN, RIGHT ANTERIOR MEDIAL SHOULDER, EXCISION:
-INVASIVE MALIGNANT MELANOMA, NODULAR TYPE WITH ULCERATION, BRESLOW'S DEPTH 7 MM, CLARK'S LEVEL IV, MARGINS NARROWLY CLEAR (SEE MELANOMA SUMMARY AND COMMENT).

GROSS EXAMINATION
SKIN, RIGHT ANTERIOR MEDIAL SHOULDER: Labeled "right ant med shoulder" is a 2.6 x 2.0 cm ovoid gray-tan irregular skin excised to a depth of 0.8 cm. The skin surface displays an eccentric 1.5 x 1.4 cm white-tan to dark brown nodule. No orientation provided. Inked, sectioned. ES (4) as follows:

1A: Tips
1B-1D: Remainder of Specimen

Specimen: Right shoulder

MELANOMA CANCER SUMMARY

[MACROSCOPIC]	
SPECIMEN TYPE:	Excision, ellipse
MACROSCOPIC TUMOR:	Present
TUMOR SITE:	Right anterior medial shoulder
LESION SIZE:	1.5 x 1.4 cm in greatest dimension
SATELLITE NODULES:	Absent
[MICROSCOPIC]	
HISTOLOGIC TYPE:	Nodular melanoma
ULCERATION:	Present
DEPTH OF INVATION/BRESLOW'S DEPTH:	7mm
CLARK'S LEVEL:	IV
GROWTH PHASE:	Vertical
REGRESSION:	Absent
MITOTIC INDEX:	High (Greater than 20 mitotic figures per mm squared)
ANGIOLYMPHATIC INVASION:	Absent
NEUROTROPISM:	Absent
TUMOR INFILTRATING LYMPHOCYTES:	Present (non-brisk)
MICROSCOPIC SATELLITES:	Not present in tissue submitted
MARGINS:	Invasive melanoma within 2 mm of peripheral margin
LYMPH NODES:	Not submitted
PATHOLOGIC STAGING (PTNM)	pT4b, pNX, pMX

Orchard Pathology Laboratories, Inc.
Robert Bush, MD, Laboratory Director
CLIA ID#: 01D000XXX000
CAP #: 123456

701 Congressional Blvd.
Carmel, Indiana 46032
Phone: (800) 555-1234
Fax: (317) 573-2528

Patient Name:	Patient, Julie B.	**Provider:**	James Provider, MD
Sex:	F	**Account Number:**	
DOB:	09/05/1968	**Client:**	ABC Medical
Patient ID:	444222	**Client Address:**	1234 Anystreet Anytown, USA 12345
Collection Date:	09/15/2013 17:45		
Received Date:	09/15/2013 18:52	**Telephone:**	(123) 555-1234
Reported:	09/16/2013 10:44	**Accession #:**	S07-6825

IMMUNOHISTOCHEMISTRY	
HMB45	Positive
S100	Positive
MELAN A	Positive

John Pathologist

John Pathologist, M.D.
Board Certified in Anatomic and Clinical Pathology
Authenticated by Pathologist: 09/16/2013 10:31

Orchard Software Corporation
(800) 856-1948 • www.orchardsoft.com

Sample reports generated from Orchard's test databases.

© Copyright 2018 Orchard Software Corporation. All rights reserved.